

Seymour Katz, M.D., Series Editor

New Advances in Surgical Treatment of Crohn's Disease



Sharon L. Stein



Fabrizio Michelassi

Despite many advances in medical treatment of Crohn's disease, the majority of patients continue to require surgical intervention at some point in their disease process. New advances in surgical techniques tend to focus on improving quality of life for patients with Crohn's disease, while minimizing level of invasiveness. In the appropriate setting, strictureplasty revision now replaces resection of small bowel, laparoscopic procedures can be performed rather than open surgery, a restorative procedure may infrequently eliminate permanent ileostomy, and an anal fistula plug alleviates loss of continence. Each of these fields is continuing to progress and change the way we treat Crohn's patients. This article reviews some of the findings for each of these techniques and their impact and applicability to patients with Crohn's disease.

INTRODUCTION

Crohn's disease is a chronic inflammatory disease of the gastrointestinal tract first described by Crohn, Ginzberg and Oppenheimer in 1932. Incidence of the disease is estimated at eight per 100,000 with a prevalence of 170 per 100,000 (1). Transmural inflammation and lymphoid aggregates differentiate

Sharon L. Stein, M.D., Assistant Professor of Surgery, Section of Colon and Rectal Surgery, New York Presbyterian Hospital, Weill Cornell Medical Center, New York, NY 10021. Fabrizio Michelassi, M.D., Lewis Atterbury Stimson Professor and Chairman, Department of Surgery, Weill Cornell Medical College, Surgeon-in-Chief, New York Presbyterian Hospital-Weill Cornell Medical Center, New York, NY.

Crohn's disease from ulcerative colitis and may occur in contiguous or classic "skip" lesions anywhere from the mouth to the anus. Although medical management may improve or even remit symptoms of Crohn's disease, there is no cure for the disease. Complications including strictures, abscess, fistulas, perforation, hemorrhage, toxic dilation, and malignancy can occur and necessitate surgical treatment. Approximately 80% of patients diagnosed with Crohn's disease require operative intervention at some point in their life (2). Of these patients 20%–70% will undergo a second surgical procedure in the course of their disease (3,4).

Given the high rate of re-operative intervention and recurrent disease, recent advances in the surgical treatment of Crohn's disease have focused on bowel sparing, minimizing invasiveness, and improving

quality of life. These techniques include strictureplasty, laparoscopy, ileoanal pouch and fistula plugs. This paper will review new technologies and areas of ongoing investigation in the advancement of surgical treatment of Crohn's disease.

STRICTUREPLASTY

Traditional management of Crohn's disease is resection and re-anastomosis of the affected segment of bowel. However, because of the recurrent nature of Crohn's disease, patients who require repeated surgical interventions and significant bowel resections may develop complications associated with decreased absorptive capacity following multiple bowel resections. In these patients, preservation of bowel length is of paramount importance. Strictureplasty, in which the bowel diameter is increased via surgical revision techniques, spares resection of the bowel (Figure 1). It was first described for the treatment of intestinal tuberculosis in the late 1970's and then described in Crohn's disease in 1982 by Lee and Papaioannou (3).

There are multiple benefits of strictureplasty including regression of disease, mucosal healing, preservation of intestinal length and low recurrence rates. Several

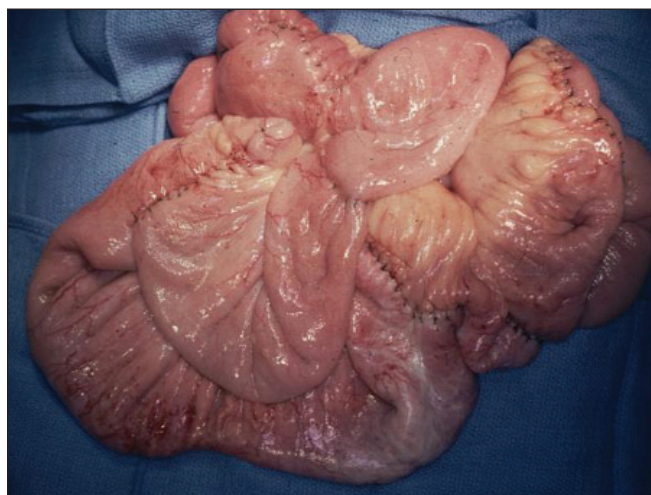


Figure 1. Multiple Strictureplasties in Patient with Crohn's Disease. This photo illustrates a common occurrence, multiple strictures in close proximity in a patient with Crohn's disease. Traditionally, the entire segment would require resection. Through the use of multiple strictureplasties, the bowel remained in situ and areas of obstruction were relieved. (Courtesy of Fabrizio Michelassi, MD.)

studies have demonstrated regression of disease and mucosal healing on gross exam after strictureplasty. Poggioli demonstrated complete mucosa healing following side to side enterocolic anastomosis on follow-up endoscopy in five patients(5), Michelassi, et al found radiographic resolution of active disease in all twelve patients undergoing side to side isoperistaltic strictureplasty with small bowel follow through. Signs of chronic or quiescent disease were noted in five patients, but not at the original surgical site (6). The important question of whether bowel preserved by strictureplasty regains physiologic absorptive function after surgery, still needs to be studied and evaluated.

Evidence from multiple studies suggests recurrence rates for localized disease are lower following strictureplasty than resection. Fichera, et al found a reduction of recurrence at the surgical site from 70% for patients undergoing resection to only 45% for patients who had strictureplasties performed (7). Over 70% of patients undergoing strictureplasty for active Crohn's disease were recurrence free at 41 months in data gathered by Roy, et al (8).

Although initially strictureplasty was used only conservatively, applications are now applied more liberally. Initially, ileocolic disease was believed to be a contraindication for revision techniques, but studies have demonstrated significant and lasting success for patients with terminal ileitis (5). Active disease was shown to be treated successfully as well; Roy, et al used strictureplasty on fourteen patients with active disease with good results (9). Lastly the success of strictureplasty was demonstrated in long segment disease in an international study by Michelassi, et al with minimal morbidity and mortality (10).

Continued study and experience in strictureplasty is needed. Options for bowel revision rather than resection are increasing rapidly. Prevention of malabsorption, nutritional supplementation and diarrhea associated with significant bowel resections by bowel revision surgery would have a substantive and significant affect on the lives of many patients with Crohn's disease. Importantly, strictureplasty is not a replacement for resection in certain presentations including patients with peritonitis, severely strictured bowel with loss of intestinal lumen or in the presence of malignancy.

(continued on page 38)

(continued from page 36)

MINIMALLY INVASIVE SURGERY

Laparoscopic surgery has now been applied to a wide variety of diseases of the intestine, both malignant and benign with great success. Benefits of laparoscopy include reduced ileus and hospital stay. Many young patients with Crohn's disease are interested in the cosmetic advantages of laparoscopic surgery, but more importantly, laparoscopy may reduce postoperative adhesions facilitating re-operative surgery in a population with a high likelihood of recurrent disease and need for surgical intervention.

Only two randomized trials of laparoscopic versus open surgery exist in the literature. In a randomized controlled trial of open versus laparoscopic ileocectomy, Milson, et al found improved pulmonary function, shorter duration of ileus and shorter hospital stay for patients undergoing laparoscopic surgery (11). These results were largely mimicked in a study by Maartense, et al who found that although following surgery quality of life scores were similar between the two groups, morbidity, cost and hospital stays were improved in the laparoscopic group (12). Tan and Tjandra made several important observations in their 2006 meta-analysis of laparoscopic surgery in Crohn's disease. They noted longer operative times, but decreased hospital length of stay and duration of ileus for laparoscopically treated patients. In addition, conversion rates in the literature range from 4.8% to 29.2% and reasons cited include the presence of inflammatory masses, abscess, fistulas and adhesions. Recurrence rates were noted to be similar between the two groups. Costs of laparoscopic surgery were lower when measured in terms of in-hospital and indirect costs due to quicker post-operative recovery (13).

It is important to note that laparoscopic surgery for Crohn's disease does take significant proficiency. Inflammation, fistula and abscess as well as thickened mesentery can make laparoscopic surgery difficult (Figure 2). Tan and Tjandra noted duration of operation, rate of conversion, length of hospital stay and morbidity rates all correlated with surgeon experience (13). A bimodal learning curve has been noted, first as surgeons gain experience with basic Crohn's laparoscopic surgery and then a second increase in duration and conversion rate as surgeons attempt increasingly complicated cases. Recommendations are that surgeons perform between ten and fifty cases to achieve

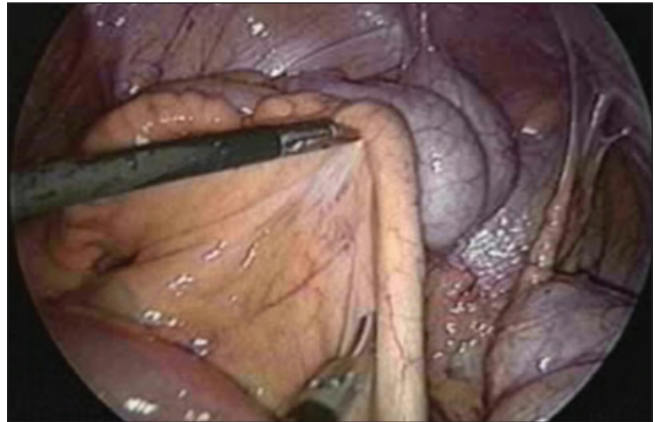


Figure 2. Laparoscopic Adhesiolysis in Patient with Crohn's Disease. One of the difficulties in performing laparoscopic surgery in Crohn's patients is the presence of thickened mesentery and multiple adhesions as shown in this photo. (Courtesy of Fabrizio Michelassi, MD.)

competency in laparoscopic surgery for Crohn's disease (14). However in capable and experienced hands, many procedures can now be successfully performed laparoscopically on patients with Crohn's disease, including reoperative surgery and bowel obstructions.

CROHN'S DISEASE AND THE ILEOANAL POUCH

The ileoanal pouch is a procedure performed following proctectomy which restores anal continence. By creating a pouch, patients have an enlarged reservoir which decreases frequency of defecation and helps improve patient continence. Although preserving patient autonomy and function in many cases, complications of failed pouches include pouchitis, fistula and recurrence of disease within the pouch. Historically, patients with Crohn's disease were not offered restorative procedures such as an ileal pouch anal anastomosis because of high rates of complications necessitating resection and further loss of intestinal length. Instead, patients requiring proctectomies were offered only permanent end colostomy or ileostomy.

In recent years, controversy has centered over whether certain patients with Crohn's disease should be offered ileoanal pouch anastomosis. Some studies of patients with Crohn's disease limited to the colon have shown complication rates as low as 30% and pouch preservation rates as high as 90% argue for the option, while others demonstrate complication rates over 90% with pouch excision in almost

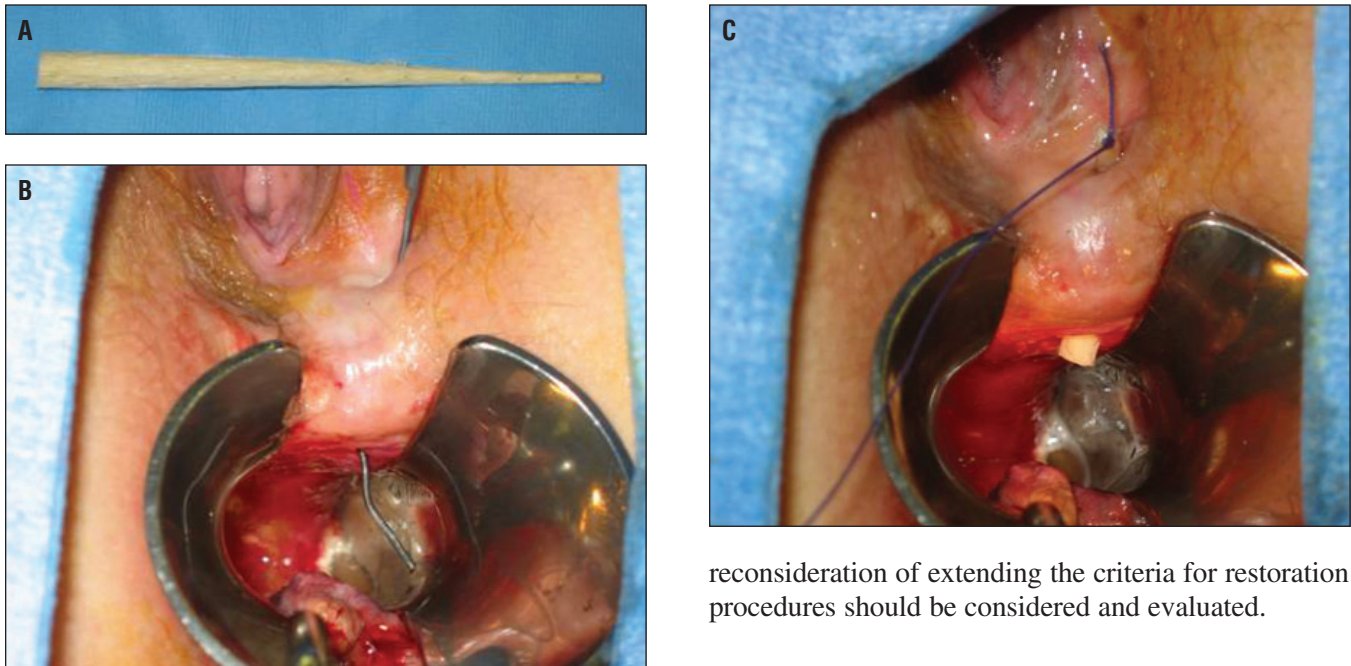


Figure 3.

- a.** Anal fistula plug derived from porcine intestinal submucosa.
b. Anal fistula demonstrated with probe.
c. Anal fistula following placement of intestinal plug.
 (Photos Courtesy of Sang Lee, MD)

one third of patients (15,16). Much of the data on pouches in Crohn's patients comes from patients with preoperative diagnosis of ulcerative colitis or indeterminate colitis and whom were diagnosed with Crohn's only after detailed pathologic evaluation or recurrence of Crohn's symptoms following colectomy.

Patients with Crohn's disease or indeterminate colitis have a recognized increased incidence of complications including pouchitis, and decreased functional outcome when compared with patients undergoing the same procedure for ulcerative colitis. Current recommendations are patients with indeterminate colitis should be considered for an ileoanal pouch anastomosis only after appropriate counseling. In addition, ileoanal pouch anastomosis can be considered for a very select group of patients with Crohn's disease without signs of small intestine or perianal disease after consultation and counseling in specialized centers in the context of ongoing evaluative studies. However, as medical treatment of Crohn's continues to improve,

reconsideration of extending the criteria for restoration procedures should be considered and evaluated.

FISTULA PLUGS

Perianal disease, in the form of abscess, fistulas, ulcers and strictures, occurs in approximately 20% of patients with Crohn's disease (17). Symptoms of perianal disease include pain, drainage, loss of continence and systemic infection. Treatment centers on drainage of collections and relief of symptoms while preserving continence.

Fistulas are abnormal connections between the internal surface of the anal canal and perianal skin. Fistulas cause drainage to the perianal skin with resultant irritation, rashes and pruritis. Most importantly, when fistulas stop draining an abscess may form causing pain, inflammation and even sepsis.

Recent advances have improved the treatment of deep anal fistulas. Medically, the addition of biologics to the medical arsenal has shown significant results. Antibiotics and infliximab are often used in conjunction with surgical drainage or seton placement. Reduction of fistula drainage may be seen in up to 60% of patients, although recurrence rates are high (18).

Surgical treatment consists of drainage of the fistula tract and any related abscess. In Crohn's patients fistulotomy or opening of fistula tract is reserved for only the most superficial of anal fissures. Any fistula that crosses the sphincter muscles may be a significant problem for patients with Crohn's disease. Inflamma-

tion inherent to the disease process impedes normal healing of the fistula tract and result in a larger and more complicated wound in patients with Crohn's disease. Deep fistulas cross the sphincter muscles and fistulotomy or fistulectomy often leads to incontinence or soilage. Draining setons, usually a suture or small plastic loop, are used as wicks to allow the tract to remain open and prevent formation of an abscess, and often alleviate symptoms but rarely contribute to healing.

Also promising is the introduction of the Surgisis® anal plug (Cook Surgical, Inc., Bloomington, IN) (Figure 3). Made from bioabsorbable xenograft of porcine submucosal, the plug is placed into the fistula tract by a surgeon in the operating room and used as an acellular matrix for local fibrotic reaction. Over time, the fistula tract closes over with penetration of normal healthy tissue into the acellular matrix. The anal plug may be used with biologics and antibiotics, as it does not create a foreign body reaction with accompanying risks of infection. It is placed in the operating room, usually under local anesthesia or sedation. Initial results from the inventors of the plug demonstrate an 80% success rate in closure of fistula tract in a mixed population (19). However, data recently presented from several independent sources demonstrated only a 25%–50% success rate in patients with Crohn's disease (20,21).

When other methods fail, surgical intervention may include rectal advancement flaps, which close the internal opening of the fistula with healthy tissue from the rectum. Despite these maneuvers, up to 30% of patients with perianal disease may require fecal diversion, permanent or temporary, for treatment of their disease (22). Work is continuing on finding more successful methods of treating anal fistulas in this difficult population.

CONCLUSIONS

Surgical treatment of Crohn's disease focuses on minimizing interventions and optimizing quality of life.

Advances in surgical technique such as the use of stricturoplasty and laparoscopic surgery, re-examination of current beliefs regarding inclusion criteria for procedures and innovation in new technologies such as the invention of fistula plugs will improve our treatment of patients with Crohn's disease and the quality of our patients' lives. ■

References

- Loftus EV Jr, Silverstein MD, Sandborn WJ, Tremaine WJ, Harmsen WS, Zimmeister AR. Crohn's Disease in Olmsted County, Minnesota, 1940-1993: Incidence, Prevalence and Survival. *Gastroenterology*, 1998; 114:1161-1168.
- Fazio VW, Wu JS. Surgical Therapy for Crohn's Disease of the Colon and Rectum. *Surg Clin North Am*, 1997; 77:197-210.
- Lee ECG, Papaioannou N. Minimal Surgery for Chronic Obstruction in Patients with Extensive or Universal Crohn's Disease. *Ann R Coll Surg Eng*, 1982; 64:229-233.
- Hurst RD, Michelassi F. Stricturoplasty for Crohn's disease: Techniques and Long-Term Results. *World J Surg*, 1998; 22(4): 359-363.
- Poggioli G, Stocchi L, Laureti S, Selleri S, Marra C, Magalotti C, Cavallari A. Conservative Surgical Management of Terminal Ileitis. *Dis Colon Rectum*, 1997; 40: 234-239.
- Michelassi F, Hurst RD, Melis M, Rubin M, Cohen R, Gasparitis A, Hanauer SB, Hart J. Side-to-Side Isoperistaltic Stricturoplasty in Extensive Crohn's Disease. *Ann Surg*, 2000; 232(3):401-408.
- Fichera A, Locadina S, Rubin M, Cimino F, Hurst RD, Michelassi F. Patterns and Operative Treatment of Recurrent Crohn's Disease: A Prospective Longitudinal Study. *Surgery*, 2006;140(4): 649-654.
- Roy P, Kumar D. Intervention-free Interval following Stricturoplasty for Crohn's Disease. *World J Surg*, 2006;30:1020-1026.
- Roy P, Dumar D. Stricturoplasty for Active Crohn's Disease. *Int J Colorectal Dis*, 2006; 21:427-432.
- Michelassi F, Taschieri A, Tonelli F, Sasaki I, Poggioli G, Fazio V, Upadhyay G, Hurst R, Sampietro GM, Fazi M, Funayama Y, Pierangeli F. An International Multicenter Prospective Observational Study of the Side-to-Side Isoperistaltic Stricturoplasty in Crohn's Disease. *Dis Colon Rectum*, 2006; 50:277-284.
- Milsom JW, Hammerhofer KA, Bohm B, Marcello P, Elson P, Fazio VW. Prospective Randomized Trial Comparing Laparoscopy vs Conventional Surgery for Refractory Ileocolic Crohn's Disease. *Dis Colon Rectum*, 2001; 44:1-9.
- Maartense S, Dunker MS, Slors JFM, Cuesta MA, Pierik EGJM, Gouma DJ, Hommes DW, Sprangers MA, Bemelman WA. Laparoscopic-Assisted Versus Open Ileocolic Resection for Crohn's Disease. *Ann Surg*, 2006; 243:143-149.
- Tan JY, Tjandra JJ. Laparoscopic Surgery for Crohn's Disease: A Meta-Analysis. *Dis Colon Rectum*, 2007; 50:576-585.
- Evans J, Poritz L, MacRae H. Influence of Experience on Laparoscopic Ileocolic resection for Crohn's Disease. *Dis Colon Rectum*, 2002; 45:1595-1600.
- Regimbeau JM, Panis Y, Pocard M, Bouhnik Y, Lavergne-Slove A, Rufat P, Matuchansky C, Valleur P. Long-term Results of Ileal Pouch Anal Anastomosis for Colorectal Crohn's Disease. *Dis Colon Rectum*, 2001; 44:769-778.
- Braveman JM, Schoetz DJ, Marcello PW, Roberts PL, Coller JA, Murray JJ, Rusin LC. The Fate of the Ileal Pouch in Patients Developing Crohn's Disease. *Dis Colon Rectum*, 2004; 47:1613-1619.
- Lapidus A. Crohn's Disease in Stockholm County During 1990-2001: an Epidemiologic Update. *W J Gastroenterol*, 2006;12:75-81.
- Present DH, Rutgeerts P, Targan S, Hanauer SB, Mayer L, Van Hogezaand RA, Podolsky DK, Sands BE, Braakman T, deWoody KL, Schaible TF, van Deventer SJH. Infliximab for the Treatment of Fistulas in Patients with Crohn's Disease. *NEJM*, 1999;340: 1398-1405.
- Kodner IJ, Mazon A, Shemesh EI, Fry RD, Fleshman JW, Birnbaum EH. Endorectal Advancement Flap Repair of Rectovaginal and Other Complicated Anorectal Fistulas. *Surgery*, 1993; 114:682.
- Ky AJ, Sylla P, Kim SA, Steinhagen RM. Short Term Results in the Treatment of Anal Fistula with Surgisis. Podium Presentation ASCRS, June 2007.
- Safar B, Jobanputra S, Cera S, Sands D, Weiss EG, Vernava AM, Nogueras JJ, Wexner SD. Anal Fistula Plug: Initial Experience and Outcomes. Podium Presentation ASCRS, June 2007.
- O'Connor L, Champagne BJ, Ferguson MA, Orangio GR, Schertzer ME, Armstrong DN. Efficacy of Anal Fistula Plug in Closure of Crohn's Anorectal Fistulas. *Dis Colon Rectum*, 2006; 49:1569-1573.